



## Retrospective study of spontaneous bone regeneration after decompression of large odontogenic cystic lesions in children

Retrospektivna studija spontane regeneracije kosti posle dekompresije velikih odontogenih cističnih lezija kod dece

Marko Pejović\*, Jelena Stepić\*, Aleksa Marković\*, Miroslav Dragović\*,  
Biljana Miličić†, Snježana Čolić\*

\*Clinic of Oral Surgery, †Department of Medical Statistics and Informatics, Faculty of Dental Medicine, University of Belgrade, Belgrade, Serbia

### Abstract

**Background/Aim.** Surgical treatment of odontogenic cysts in childhood could be accompanied by injury of important anatomical structures. Even though enucleation is considered to be preferable treatment of odontogenic cysts, the specificities of pediatric age favor more conservative surgical approach. The aim of this study was to assess the effectiveness of decompression as the uttermost treatment of odontogenic cysts in the pediatric age. **Methods.** This retrospective study included 22 patients, 7–16 years old, with a single jaw cystic lesion. The majority of these lesions were dentigerous cyst (14), and the rest belonged to keratocystic odontogenic tumor (KCOT) (8). All lesions were primarily treated with decompression; it was a final treatment (one-stage procedure) in 13 dentigerous cysts, and it was followed by enucleation (two-stage procedure) in one dentigerous cyst and all the KCOT. **Results.** A total of 13 (59.1%) dentigerous cysts were treated successfully only with decompression as one stage procedure, while the other 9 (40.9%) cysts required enucleation (1 dentigerous and 8 KCOT), after decompression ( $p \leq 0.001$ ). **Conclusion.** Related to non-aggressive lesions, more conservative treatment approach, such as decompression as one-stage procedure, should be considered. On the other hand, KCOTs in children require a two-stage procedure for a successful treatment outcome.

### Key words:

odontogenic cysts; oral surgical procedures; decompression, surgical; treatment outcome; pediatric dentistry.

### Apstrakt

**Uvod/Cilj.** Hirurška terapija odontogenih cista u dečjem uzrastu može da bude udružena sa povredama važnih anatomskih struktura. Mada se enukleacija smatra terapijom izbora viličnih cista, specifičnosti dečjeg uzrasta nameću primenu konzervativnijeg hirurškog pristupa. Cilj istraživanja bio je da se proceni efikasnost dekompresije kao definitivnog terapijskog modaliteta kod odontogenih cista u dečjem uzrastu. **Metode.** Ova retrospektivna studija obuhvatila je 22 pacijenta, uzrasta 7–16 godina, sa solitarnim cističnim lezijama. Najčešće među njima su bile folikularne ciste (14), a ostale su bile keratocistični odontogeni tumori (KCOT). Sve cistične lezije prvo su tretirane dekompresijom; to je bio i jedini poduhvat (jednofazni postupak) kod 13 folikularnih cista, a potreba za sekundarnim zahvatom – enukleacijom, ukazala se posle dekompresije jedne folikularne ciste i svih KCOT (dvofazni postupak). **Rezultati.** Ukupno 13 (59,1%) cističnih lezija, od kojih su sve bile folikularne ciste, uspešno je podvrgnuto jednofaznom hirurškom postupku, dok je preostalih 9 (40,9%) cista (1 folikularna i 8 KCOT) zahtevalo naknadnu enukleaciju. **Zaključak.** Kod neagresivnih cističnih lezija preporučuje se konzervativniji hirurški pristup kao što je dekompresija (jednofazna procedura). Nasuprot tome, KCOT u dečjem uzrastu zahtevaju dvofazni hirurški postupak – dekompresiju praćenu enukleacijom.

### Ključne reči:

ciste, odontogene; hirurgija, oralna, procedure; dekompresija, hirurška; lečenje, ishodi; stomatologija, dečija.

### Introduction

Although the frequency of odontogenic cysts is relatively low in children, three-dimensional growth of maxillofacial

skeleton as well as odontogenesis of deciduous and permanent dentitions during the pediatric age might be associated with developmental jaw cysts formation<sup>1, 2</sup>. When occur, they exhibit rapid growth and large size, causing bone expansion,

displacement of adjacent teeth, root deformation of developing permanent teeth or an intraoral buccal swelling<sup>3</sup>. Treatment of such lesions is solely surgical.

An aggressive management of large cysts in children can have an adverse effect on tooth development, eruption process, and growth of the involved jaw<sup>4</sup>. Therefore, less aggressive surgical treatment might be beneficial for pediatric patients due to anatomic specificities of the growing facial bones, existence of permanent tooth germs, faster bone repair process<sup>5</sup>, and difficulties in cooperation. Decompression through an opening into the cystic cavity releases intramural pressure, favors formation of new bone, provides not only preservation of neurovascular and other anatomic structures but also minimal morbidity and low rate of surgical complications, including possible recurrence and decreased aggressiveness of the lesions<sup>6, 7</sup>. Therefore, a conservative treatment approach is especially interesting to be performed in patients of pediatric age.

In the literature there is not much information relating to conservative surgical treatment approach to odontogenic jaw cysts in childhood. The aim of this retrospective study was to evaluate the effectiveness of decompression as the uttermost treatment of large odontogenic jaw cysts in pediatric age.

## Methods

A total of 22 young and healthy patients (15 males, 7 females) with a large odontogenic cystic lesion treated by decompression between the year 2002 and 2011 were included in this research. The mean age of the patients was  $11.3 \pm 2.9$  (range 7.5–16) years. Referring to histopathological finding, there were 14 dentigerous cysts and 8 keratocystic odontogenic tumors (KCOT). The data were collected reviewing medical files and panoramic radiographs of patients under the age of sixteen, who were subjected to decompression of odontogenic cystic lesions  $> 2$  cm in diameter. The patients with confirmed nevoid basal cell carcinoma syndrome, as well as patients with small, multiple or recurrent lesions, were excluded from the research.

Clinical data, such as patient age and gender, chief complaints, localization and size of the lesion, affected teeth, decompression time, definite surgery modality, complications, recurrences, follow-up period and the histopathological diagnosis were recorded. The size of the cyst and its relation to the teeth and adjacent structures were evaluated and compared on panoramic radiographs made before and after the decompression. The size of the cyst was recorded as maximal vertical diameter (in cm), maximal horizontal diameter (in cm) and their multiplication (in  $\text{cm}^2$ ) named standard lesion area index (SLAI)<sup>8</sup>.

All cystic lesions were treated with decompression performed by one experienced oral surgeon under local anesthesia (2% lidocaine with epinephrine 1:100,000). Decompression implied small bony window preparation for opening the cystic lesion cavity and biopsy sample collection at the same time. The opening was maintained either by polyethylene tube or iodoform gauze. A polyethylene tube was placed in the socket if deciduous tooth was extracted simultaneously or

otherwise on the top of the alveolar ridge and fixed by suturing to surrounding mucosa. Whenever the tube was instable or the cyst was positioned buccally, the opening was maintained with iodoform gauze replaced after irrigation. All the remaining cavities were rinsed with sterile saline solution three times a week.

Control radiographic examinations were performed in a 4-month period. Control radiographs were used to evaluate the treatment success – the size of the remaining cavity and the position of the impacted teeth. Irrigation was performed until the remaining cavity had been shrunk completely or tooth erupted spontaneously. Just in cases where a part of the dentigerous cyst stayed trapped or when KCOT was diagnosed, enucleation was performed in the second act, when panoramic radiograph showed a significant reduction in the size of the remaining cavity without involving vital anatomical structures. In addition, Carnoy solution was always used in order to minimize the recurrence rate of KCOT.

One year after the end of the therapy an independent observer evaluated bone regeneration of the treated area.

This study was approved by the local institutional board. The principles outlined in the Declaration of Helsinki were followed.

## Statistical analysis

For comparison between different histopathological findings Student's *t*-test, the  $\chi^2$  test, Fisher's test and Mann-Whitney *U* test were used. Univariate and multivariate binary logistic regression analysis were used to evaluate the relationship between different odontogenic cystic lesion and potential determinants. The results were expressed as the odd ratios (OR) and their 95% confidence intervals (CI). Statistical analyses were performed using SPSS (SPSS version 19.0 Inc., IBM Chicago). A statistical significance was defined as  $p < 0.05$ .

## Results

According to localization of lesions, there was no significant difference between jaws (Table 1). Nevertheless, it was found that 6 out of 14 dentigerous cysts were located in the maxilla (3 in the frontal region, 1 in the posterior region and 2 affected both of frontal and posterior region). The remaining 8 were in the mandible (7 in the posterior region and 1 extending to the frontal region). KCOTs were localized as follows: 3 were in the maxilla (1 in the frontal region, 1 in the posterior and 1 spreading from anterior to posterior region), and 5 in the mandible, predominately in the angle/ramus, except 1, which was found in the region of the lower canine.

Although the average size of KCOTs was higher than the average size of the dentigerous cysts, there was no significant difference as between jaws (Table 1). There was a significant difference between the mean age of the patients with KCOTs and those with dentigerous cysts (Table 1).

A total of 15 (68.2%) cysts were discovered accidentally while 7 (31.8%) cysts (5 dentigerous and 2 KCOTs) had some clinical symptoms (swelling, oozing cystic fluid, etc.), but without anyone being predominant. A

**Table 1**  
**Demographic and clinical characteristics of patients regarding histopathological (HP) findings**

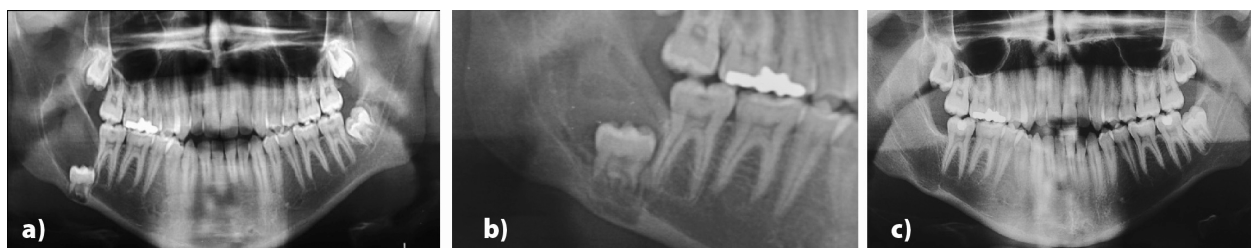Patient and lesion characteristics	HP findings		<i>p</i>
	Dentigerous cyst	KCOT	
Gender, n (%)			
male	9 (64.3)	6 (75.0)	0.490
female	5 (35.7)	2 (25.0)	
Age (years), $\bar{x} \pm SD$ ; med; min-max	9.5 $\pm$ 1.5; 9.0; 7.5-13	14.3 $\pm$ 2.2; 15.75; 11-16	$\leq 0.001^*$
Size (cm <sup>2</sup> ), $\bar{x} \pm SD$ ; med; min-max	4.2 $\pm$ 1.5; 4.2; 2.0-7.1	6.6 $\pm$ 4.07; 6.06; 2.6-15	0.143 <sup>a</sup>
Jaw, n (%)			
maxilla	6 (42.9)	3 (37.5)	0.584 <sup>c</sup>
mandible	8 (57.1)	5 (62.5)	
Therapeutic method, n (%)			
decompression	13 (92.9)	0 (0)	$\leq 0.001^{*c}$
decompression + enucleation	1 (7.1)	8 (100.0)	
Decompression time (months), $\bar{x} \pm SD$ ; med; min-max	6.9 $\pm$ 1.7; 6.0; 6-12	10.3 $\pm$ 3.2; 10.5; 6-16	0.006 <sup>*b</sup>

<sup>a</sup>*t*-test; <sup>b</sup>Mann-Whitney *U*-test; <sup>c</sup>Fisher's test; \*statistically significant; SD – standard deviation; med – median; KCOT – keratocystic odontogenic tumor.

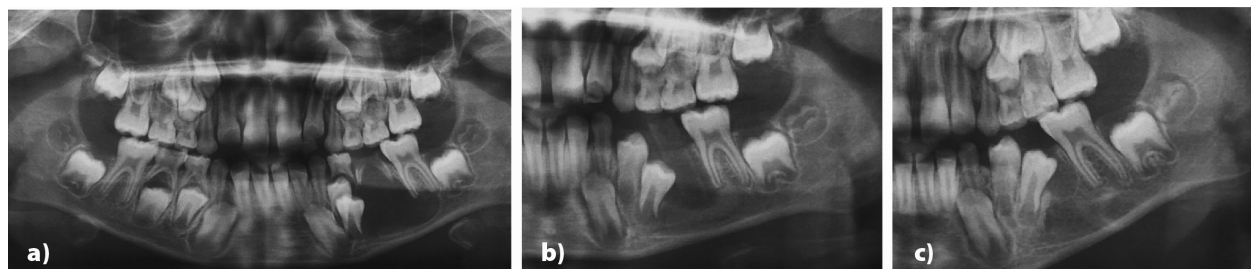
total of 13 cysts were treated successfully only with the one-stage procedure while the other 9 required enucleation (Table 1). The mean duration of decompression was  $8.2 \pm 2.9$  months for all cystic lesions, regardless of histopathological findings. We found that the mean duration of decompression was significantly shorter in those patients who had been treated only by decompression ( $7.00 \pm 0.5$  months,  $p = 0.022$ ). The mean duration of decompression preceding enucleation was  $9.9 \pm 1.1$  months, which was significantly different. Minimal duration of decompression was 6 months and maximal one 16 months.

It was discovered that 75% of KCOTs had impacted to-

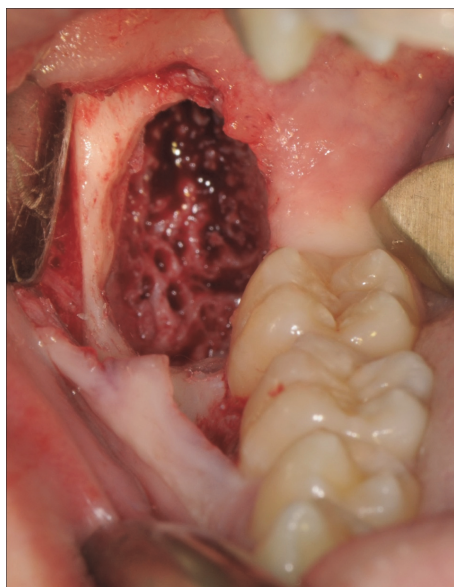oth in the cystic lumen (Figures 1a and b). It was the third molar that was impacted most often (83.33%) and all of them were extracted during enucleation (Figure 1c); 10 (77.77%) dentigerous cysts were associated with premolars – 8 (66.66%) mandibular and 2 (11.11%) maxillary. A total of 4 (22.22%) maxillary dentigerous cysts were associated with the canine. Just in one (7.14%) case the affected tooth was extracted, while in 13 (92.86%) patients the affected teeth were saved; of these, 12 (85.72%) teeth erupted spontaneously and 1 (7.14%) needed orthodontic traction (Figure 2a-c). Figure 3 shows the rough surface of active bone deposition favored by decompression in one patient.



**Fig. 1** – Preoperative panoramic radiograph shows a large radiolucent cystic lesion with the impacted third molar located at the base of the mandible [keratocystic odontogenic tumor (KCOT)]; b) Six months after decompression, the impacted third molar was moved to a more suitable position, making extraction much easier. Ongoing bone deposition decreased a defect, making enucleation less traumatic; c) Three years after enucleation, panoramic radiograph shows a complete healing of the former bone defect, without any suspicious sign of a recurrence.



**Fig. 2** – a) Panoramic radiograph shows a dentigerous cyst involving permanent premolars germs; b) After four months of decompression, radiograph view shows a polyethylene tube in the defect and newly formed bone layer with permanent premolars' germs eruption through cystic cavity; c) After nine months of decompression, a panoramic radiograph shows complete resolution of the lesion and moving the involved teeth into physiologically determined position within dental arches.



**Fig. 3 – Clinical view showing the rough surface of active bone deposition favored by decompression.**

All cystic lesions showed a complete osseous regeneration after enucleation, without complications. The mean duration of follow-up was  $3.41 \pm 1.9$  years, and no recurrences were noted.

### Discussion

Childhood is characterized by more frequency of developmental odontogenic cysts<sup>1</sup>, what is in contrast with the adult period<sup>2,9</sup>, dominated by inflammatory cysts. This could be explained by the fact that in pediatric age the maxilla-mandibular complex is characterized by active growth as well as development of primary and permanent dentition. All that can be correlated with the appearance of developmental cysts<sup>1,2</sup>. Therefore, cysts are fast growing, symptomless and usually diagnosed when they reach a considerable size, which is in agreement with our findings.

When it comes to the pediatric age the literature does not present any consensus on a uniform treatment plan for the jaw cystic lesions, especially the large ones. The primary goal of jaw cysts treatment is their complete surgical removal in order to avoid any further lesion growth, large bone defects formation, frequent infections, malignant alteration and recurrences. Therefore, the treatment of choice would generally be enucleation<sup>9,10</sup>. Sometimes however, this approach can jeopardize secondary objectives, such as preservation of adjacent important anatomical structures, vitality of affected teeth and most notably the teeth germs<sup>10</sup>. Moreover, enucleation of large cystic lesions is inevitably followed by creation of large bone defects impairing complete bone regeneration. All these considerations point to the importance of selecting less aggressive treatment modality for cystic lesions in childhood.

Although cystic lesion larger than  $3 \text{ cm}^2$  are usually indicated for decompression<sup>11</sup> this study encompassed three lesions smaller than  $3 \text{ cm}^2$ . Nevertheless, all treated lesions were more than 2 cm in diameter, which is considered to be

large cystic lesion in children<sup>12</sup>, especially concerning small dimensions of alveolar ridges. Removal of these lesions in a single-stage procedure would compromise important goals of treatment (preservation of adjacent important anatomical structures and vitality of the affected teeth), making decompression as more convenient treatment modality.

In 92% of dentigerous cysts shrinkage completely occurred, so decompression became the only and final treatment. Additionally, 85.7% of impacted teeth were spontaneously arranged in physiologically determined position within dental arches. These results indicate a two-fold effect of decompression. First of all, there is a great capacity of bone regeneration in pediatric age thus simultaneously providing spontaneous eruption of affected permanent teeth. At the same time, decompression guided tooth eruption encouraged successful bone regeneration, avoiding second stage surgery and orthodontic treatment (Figure 2). Complete disappearance of lesion was probably possible due to creeping substitution by normal mucosa from the edges of the lesion growing in and replacing the cystic epithelium<sup>13</sup>. In that way, decompression spontaneously turns into marsupialization, making this a definitive therapy. Our finding is consistent with the report of Anavi et al.<sup>8</sup>, showing that decompression may serve as the primary treatment of non-aggressive cystic lesions. Previous reports also emphasized that marsupialization as conservative treatment modality would be a favorable treatment of choice for extensive dentigerous cysts in children<sup>14,15</sup>.

Our study showed only one case where, following decompression, enucleation of dentigerous cyst was necessary. A potential reason for this could be a complex cyst shape not allowing appropriate irrigation of its entire lumen. Besides, position and complete root formation of impacted tooth might interfere with shrinkage, as well. On the other hand, the literature provides information that dentigerous cysts were most frequently treated with enucleation and extraction of the impacted teeth, while efforts were made to preserve usually the canines<sup>9,10</sup>. Moreover, if enucleation of extensive dentigerous cyst is performed in the first place it would lead to the loss of several teeth with potential functional, cosmetic and psychological consequences<sup>10</sup>.

Our results highlight the fact that decompression is effective in promoting very high percentage of teeth preservation (92.8%), where in 85.7% of cases the teeth erupted spontaneously, while orthodontic traction had to be used only in one (7.1%) patient. A probable reason for this high success rate might be the consequence of unfinished root formation, which gives the teeth strong eruptive power. A similar observation was made by Qian et al.<sup>16</sup>, who found that age, gender, tooth angulation and cusp depth were not significant risk factors for the eruption of the impacted teeth, but rather the level of root formation which might play an important role. On the other hand, Yahara et al.<sup>17</sup> found that patient's age may affect successful eruption of premolars in dentigerous cyst. The main age with successful eruption was in agreement with the age in our survey, while the main age of patient of the non-erupted group was significantly older. Two patients in our survey, the one with orthodontic traction and the only one in whom tooth was extracted, were elder

and with completely formed roots, so spontaneous eruption could not have been accomplished. Moreover, it was premolar that was extracted, due to dental crowding and in agreement with orthodontist.

Unlike dentigerous cysts, all KCOTs were treated with two-stage surgical approach – decompression followed by enucleation in the second act. This is due to KCOT's characteristic aggressive behavior and a remarkably high recurrent rate, up to 56%<sup>18</sup>. Even though successful marsupialization of KCOT was reported in the literature<sup>6,13</sup>, it is considered that for aggressive lesions secondary definitive surgery should be performed<sup>8,11,19</sup>. Since our results show that decompression time for reducing the half size of KCOT lasted from 6 to 16 months (Table 1), it would take much longer time for lesions to completely disappear, especially because the increase in bone density together with the decrease in cyst volume is reported to be the highest in the first 3 months<sup>20</sup>. This is why we reduced a long decompression/marsupialisation time, considering it to be the main weakness of the therapy<sup>6,21</sup> due to the possible malignant alteration of the lesion left in-site<sup>22</sup>.

The first strength of new bone apposition favored by decompression (Figure 3) is that the lesion volume was reduced providing conditions for its safer and easier removal. Therefore, none of postoperative complications were recorded in our study. Moreover, smaller bone defect after decompression contributed to complete bone regeneration, observed on all control radiograms one year after the final surgery (Figure 1). Besides, the decompression resulted in preservation of the most of the affected teeth, except for impacted ones, predominately the third molars. Only three teeth the roots of which protruded in the lesion lumen at the time of enucleation had to be extracted. Additionally, because of both bone apposition and eruptive power, the impacted tooth was moved to more suitable position, so extraction was easier to perform with lower surgical trauma and risk of injuring adjacent anatomical structures (Figure 1b).

When it comes to the recurrent rates, we did not find recurrences at all, which is far better than reported in the literature and could be explained by several things. Firstly, this is due to surgical approach combining decompression followed by enucleation with additional use of Carnoy solution. It is well-known that after decompression the keratocystic wall becomes thickened and more cohesive, which makes it easier for complete removal<sup>21</sup>. Besides, previous studies have found that decompression favors epithelial transformation into its less aggressive form (orthokeratinized epithelium) or into epithelium of normal oral mucosa<sup>6,13,21,23</sup>. Moreover, every histopathologically proven KCOT was additionally treated with Carnoy solution after excision of the lesion. The use of this was proven to successfully reduce the recurrence rate<sup>24,25</sup> by destroying epithelial residues of the cyst wall that may have been left behind in the bone defects after the

enucleation alone<sup>26</sup>. In addition, all impacted and teeth which roots protruded in the lesion lumen at the time of enucleation were extracted thus minimizing the chance for recurrence due to the possible presence of daughter cysts in the periodontal ligament and attached gingiva of affected teeth<sup>27</sup>. On the other hand, our mean follow-up period was relatively short [ $3.88 \pm 2.75$  (from 2 to 8) years]. Forssell et al.<sup>28</sup> found only 3% of KCOT's recurrences in the first year after the surgery, while within three years postoperatively, the recurrence rate rose up to 37%. According to the literature, recurrences usually appear within the first 5 years<sup>25,27,29</sup>; so it seems that longer follow-up (5 years) would give more realistic results.

Regarding decompression itself, the mean decompression time in our survey was 8.2 months regardless the type of cystic lesion. These findings are in line with the results of Anavi et al.<sup>8</sup> who pointed out that intensive skeletal growth during children's age was probably responsible for a shorter decompression time and a higher reduction rate when the results were compared to adults. In addition, our results show a significantly shorter decompression time for dentigerous cyst than for KCOT. On the contrary, Kubota et al.<sup>30</sup> found that there was no difference between the relative speed of shrinkage of dentigerous cysts and KOCT. In their study the average age of the patients was 45 years and it is quite clear that their impacted teeth had definitely lost the growth potential, what is totally different from the high growth potential in childhood. Our findings also show no significant difference between the mean decompression time for maxillary and mandibular lesions, probably due to the excellent blood supply and the ongoing growth process of pediatric patients.

## Conclusion

Within the limits of this study, we conclude that large dentigerous cysts can be successfully treated with decompression as the definite therapy method. This simple and minimally invasive approach, highly appropriate in children, provides complete bone regeneration and spontaneous eruption of the affected permanent teeth; KCOTs in children require the two-staged surgical approach – decompression followed by enucleation in the second act. Decompression of large KCOTs in children provides lower surgical trauma, easier access for extraction of impacted teeth, reduced recurrent rate and good conditions for complete bone regeneration. At the same time, general anesthesia is avoided; regenerative capacity of both jaws are similar in pediatric age.

## Acknowledgement

This study was supported by the Serbian Ministry of Education, Science and Technological Development, Grant N<sup>o</sup>, 175021.

## R E F E R E N C E S

1. Bodner L. Cystic lesions of the jaws in children. *Int J Pediatr Otorhinolaryngol* 2002; 62(1): 25–9.
2. Manor E, Kachko L, Puterman MB, Szabo G, Bodner L. Cystic lesions of the jaws - a clinicopathological study of 322 cases and review of the literature. *Int J Med Sci* 2012; 9(1): 20–6.
3. Sun KT, Chen MY, Chiang HH, Tsai HH. Treatment of large jaw bone cysts in children. *J Dent Child (Chic)* 2009; 76(3): 217–22.
4. Hyun H, Hong S, Kim J. Recurrent keratocystic odontogenic tumor in the mandible: a case report and literature review. *Oral Surg Oral Med Oral Pathol Oral Radiol Endod* 2009; 108(2): 7–10.
5. Takeda Y. Hyaline bodies and secondary dental cuticle in dentigerous cyst. *J Oral Pathol* 1985; 14(3): 268–9.
6. Nakamura N, Mitsuyasu T, Mitsuyasu Y, Taketomi T, Higuchi Y, Ohishi M. Marsupialization for odontogenic keratocysts: long-term follow-up analysis of the effects and changes in growth characteristics. *Oral Surg Oral Med Oral Pathol Oral Radiol Endod* 2002; 94(5): 543–53.
7. August M, Faquin WC, Troulis MJ, Kaban LB. Dedifferentiation of odontogenic keratocyst epithelium after cyst decompression. *J Oral Maxillofac Surg* 2003; 61(6): 678–83.
8. Anavi Y, Gal G, Miron H, Calderon S, Allon DM. Decompression of odontogenic cystic lesions: clinical long-term study of 73 cases. *Oral Surg Oral Med Oral Pathol Oral Radiol Endod* 2011; 112(2): 164–9.
9. Iatron I, Theologie-Lygidakis N, Leventis M. Intraosseous cystic lesions of the jaws in children: a retrospective analysis of 47 consecutive cases. *Oral Surg Oral Med Oral Pathol Oral Radiol Endod* 2009; 107(4): 485–92.
10. Motamedi MH, Talesh KT. Management of extensive dentigerous cysts. *Br Dent J* 2005; 198(4): 203–6.
11. Gao L, Wang X, Li S, Liu C, Chen C, Li J, Zhi K. Decompression as a treatment for odontogenic cystic lesions of the jaw. *J Oral Maxillofac Surg* 2014; 72(2): 327–33.
12. Bodner L, Woldenberg Y, Bar-Ziv J. Radiographic features of large cystic lesions of the jaws in children. *Pediatr Radiol* 2003; 33(1): 3–6.
13. Pogrel AM, Jordan RC. Marsupialization as a definitive treatment for the odontogenic keratocyst. *J Oral Maxillofac Surg* 2004; 62(6): 651–5.
14. Hu Y, Chang Y, Tsai A. Conservative treatment of dentigerous cyst associated with primary teeth. *Oral Surg Oral Med Oral Pathol Oral Radiol Endod* 2011; 112(6): 5–7.
15. Koca H, Esin A, Ayçan K. Outcome of dentigerous cysts treated with marsupialization. *J Clin Pediatr Dent* 2009; 34(2): 165–8.
16. Qian W, Ma Z, Xie Q, Cai X, Zhang Y, Yang C. Marsupialization facilitates eruption of dentigerous cyst-associated mandibular premolars in preadolescent patients. *J Oral Maxillofac Surg* 2013; 71(11): 1825–32.
17. Yabara Y, Kubota Y, Yamashiro T, Shirasuna K. Eruption prediction of mandibular premolars associated with dentigerous cysts. *Oral Surg Oral Med Oral Pathol Oral Radiol Endod* 2009; 108(1): 28–31.
18. Blanas N, Freund B, Schwartz M, Furst IM. Systematic review of the treatment and prognosis of the odontogenic keratocyst. *Oral Surg Oral Med Oral Pathol Oral Radiol Endod* 2000; 90(5): 553–8.
19. Kaczmarczyk T, Mojsa I, Stypulkowska J. A systematic review of the recurrence rate for keratocystic odontogenic tumour in relation to treatment modalities. *Int J Oral Maxillofac Surg* 2012; 41(6): 756–67.
20. Zhao Y, Liu B, Han Q, Wang S, Wang Y. Changes in Bone Density and Cyst Volume After Marsupialization of Mandibular Odontogenic Keratocysts (Keratocystic Odontogenic Tumors). *J Oral Maxillofac Surg* 2011; 69(5): 1361–6.
21. Marker P, Brøndum N, Clausen PP, Bastian HL. Treatment of large odontogenic keratocysts by decompression and later cystectomy: a long-term follow-up and a histologic study of 23 cases. *Oral Surg Oral Med Oral Pathol Oral Radiol Endod* 1996; 82(2): 122–31.
22. Falaki F, Delavarian Z, Salebinejad J, Saghafi S. Squamous cell carcinoma arising from an odontogenic keratocyst: a case report. *Med Oral Patol Oral Cir Bucal* 2009; 14(4): 171–4.
23. Pogrel AM. Treatment of keratocysts: the case for decompression and marsupialization. *J Oral Maxillofac Surg* 2005; 63(11): 1667–73.
24. Gosau M, Draenert FG, Müller S, Frerich B, Bürgers R, Reichert TE, et al. Two modifications in the treatment of keratocystic odontogenic tumors (KCOT) and the use of Carnoy's solution (CS)—a retrospective study lasting between 2 and 10 years. *Clin Oral Invest* 2009; 14(1): 27–34.
25. Stoelinga PJ. The treatment of odontogenic keratocysts by excision of the overlying, attached mucosa, enucleation, and treatment of the bony defect with carnoy solution. *J Oral Maxillofac Surg* 2005; 63(11): 1662–6.
26. Stoelinga PJ. Long-term follow-up on keratocysts treated according to a defined protocol. *Int J Oral Maxillofac Surg* 2001; 30(1): 14–25.
27. Tolstunov L, Treasure T. Surgical treatment algorithm for odontogenic keratocyst: combined treatment of odontogenic keratocyst and mandibular defect with marsupialization, enucleation, iliac crest bone graft, and dental implants. *J Oral Maxillofac Surg* 2008; 66(5): 1025–36.
28. Forssell K, Forssell H, Kahnberg KE. Recurrence of keratocysts. A long-term follow-up study. *Int J Oral Maxillofac Surg* 1988; 17(1): 25–8.
29. Pitak-Arnop P, Chaine A, Oprean N, Dhanutbai K, Bertrand J, Bertolus C. Management of odontogenic keratocysts of the jaws: A ten-year experience with 120 consecutive lesions. *J Craniomaxillofac Surg* 2010; 38(5): 358–64.
30. Kubota Y, Imajo I, Itonaga R, Takenoshita Y. Effects of the patient's age and the size of the primary lesion on the speed of shrinkage after marsupialisation of keratocystic odontogenic tumours, dentigerous cysts, and radicular cysts. *Br J Oral Maxillofac Surg* 2013; 51(4): 358–62.

Received on August 28, 2014.

Revised on November 19, 2014.

Accepted on December 8, 2014.

Online First December, 2015.